

SPIKING MORTALITY SYNDROME IN BROILER CHICKENS CLINICAL AND MORPHOLOGICAL EXAMINATIONS OF THE CASES RECORDED IN BULGARIA

DINEV I and KANAKOV D

Trakia University, Faculty of Veterinary Medicine, Stara Zagora, Bulgaria

(Received 7th August 2010)

Clinical and morphological examinations were carried out in two broiler flocks with twenty thousand chickens each. The morbidity and mortality were followed on the basis of clinical signs and gross pathological examinations. Blood samples of affected chickens were obtained for the determination of blood sugar levels. Our results showed low morbidity, high mortality and a markedly depressed growth.

Key words: broiler chickens, hypoglycemia, spiking mortality syndrome

INTRODUCTION

Spiking mortality syndrome (SMS) usually occurs in eight to eighteen day-old broiler chickens (Brown *et al.*, 1991; Craig, 1991; Davis *et al.*, 1995a).

Affected chickens become acutely hypoglycemic, with plasma glucose levels as low as 17 mg/dL (Brown *et al.*, 1991; Craig, 1991; Davis *et al.*, 1995a; Davis *et al.*, 1995b; Davis *et al.*, 1996). Hypoglycemia is the apparent physiological basis for the central nervous system signs with SMS, as the brains of chickens showing those signs are histologically normal. The etiologic agent(s) of SMS has not been identified conclusively. SMS has been experimentally reproduced with the use of homogenized intestines (Davis *et al.*, 1995b; Davis *et al.*, 1995c), feces (Davis *et al.*, 1995b; Davis *et al.*, 1995c), darkling beetles (*Alphitobius diaperinus*) collected from built-up litter (Davis *et al.*, 1996), and homogenized brains containing adenovirus-like particles (Davis *et al.*, 1997). A serotype-avian adenovirus was isolated from flocks with the naturally occurring disease (Goodwin *et al.*, 1993; Mendelson *et al.*, 1995). On the basis of liver lesions, mycotoxins or combinations of mycotoxins were thought to be involved in the etiology of the syndrome, but they have not been identified (Hess *et al.*, 1995). Other factors believed to contribute to SMS are certain diets, especially ones with high amounts of animal by-products sensitive to oxidation or management errors that would lead to stress conditions (Davis, 2003).

The purpose of this report was to describe the results from clinical and morphological investigations of field cases of SMS in broiler chickens with regard

to their utilization in the diagnostics and differential diagnosis of this problem that is insufficiently studied and new to Bulgarian poultry breeding practice.

The investigations were carried out in 2 broiler flocks (flock A and flock B) of 20,000 Ross 308 chickens each. The chickens belonged to one poultry farm, originated from one parent flock and were fed uniformly according to technological requirements. Within the same period of time, chickens at the age of 16 days (flock A) and 12 days (flock B) with nervous signs appeared and mortality rate suddenly increased.

MATERIAL AND METHODS

The morbidity and mortality rates were followed on the basis of clinical signs and gross pathological examinations. Blood samples were obtained from 15 affected and 15 healthy chickens of each flock for the determination of blood glucose concentrations by means of a biochemistry analyzer MINDRAY BA-88 with diagnostic kits of Chema diagnostica, Italy. For histological examination, specimens of viscera (liver, pancreas, duodenum, jejunum and *B. fabricii*) were obtained from 10 necropsied bodies from each flock. The material was fixed in 10% neutral formalin, processed by routine techniques and embedded in paraffin. Cross sections of approx. 5 μm were stained with haematoxylin/eosin (H/E).

RESULTS

The results of performed clinical investigations showed morbidity rates of about 2.00% / 0.5% in flocks A and B. The daily mortality rates in the flocks are shown on Fig. 1 and 2. In flock B, a sudden increase and sharp reduction of mortality occurred between the age of 11 and 13 days (Graph 1). In flock A, the daily mortality increased up to the age of 18 days, with peak values by 20-23 days and a reduction at the age of 25 days (Graph 2). The total number of dead chickens in flock B was 98 (0.49%), and in flock A – 365 (1.82%). Afterward, 480 (2.4%) survived chickens from flock A were culled because of seriously stunted growth (Fig. 1).

In the general case, various-sized groups of highly screaming chickens have been observed. The rapidly growing male broilers in a good condition were more frequently attained. Clinically, a fine subtle tremor of the head or marked depression have been noticed, and in more severe cases – coma as well. The characteristic posture of clinical manifestation was prostration, lying down on the chest and abdomen with the legs open and extended backward (Fig. 2). In some chickens, diarrhoeic signs were present, the faeces being mixed with orange-coloured mucus. Surviving chickens were usually blind.

In the gross pathological examination, the pale colour of the featherless part of bodies was the most impressive. In about 25% of studied chickens from both flocks, slight to moderate signs of enteritis were found. The intestines were empty of food content. In the lumen there was excessive fluid, especially in the posterior part of the jejunum and the ileum and accumulation of orange-coloured mucoid

(Fig. 3). In the gizzard, litter was a common finding. In almost all studied chickens, a high degree of atrophy of *B. fabricii*, thymus and spleen was present. Concomitant pathoanatomical findings were the persistent aseptic necroses of femoral heads or fractures of proximal femurs. In about 1.5% of examined chickens from flock A and over 60% of those from flock B, haemorrhages of liver parenchyma of variable intensity were detected (Fig. 4).

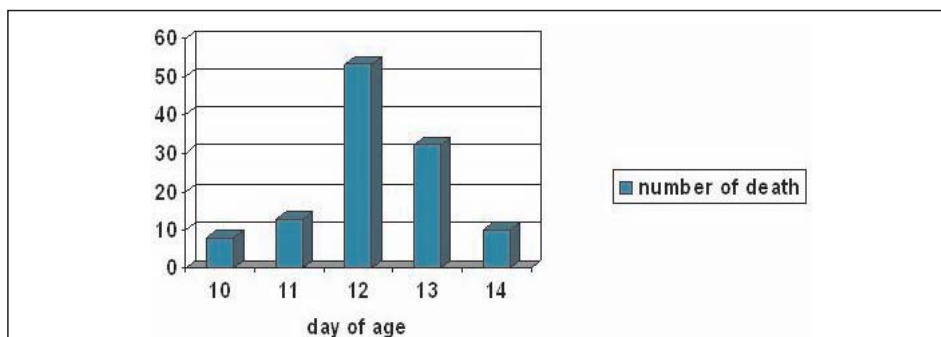
The histopathological lesions corresponded to gross anatomical ones. In all studied samples from both flocks, there was a severe lymphoid deficiency and atrophy of lymphatic follicles in the *B. fabricii* (Fig. 5). In the pancreas, there were no microscopic lesions, and in about 1/3 of studied duodenal and jejunal specimens there were alterations characteristic for a mild catarrhal enteritis in the two flocks. The liver histological lesions were massive haemorrhages with a higher incidence in birds from flock B.



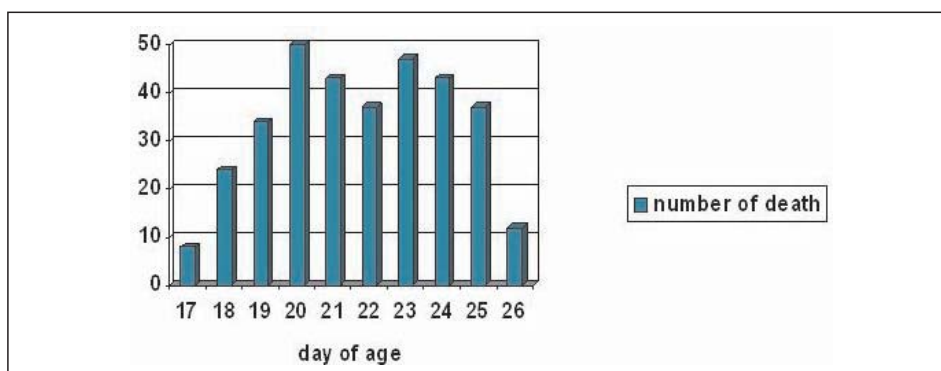
Figure 1. Seriously stunted growth in surviving chickens on the left. On the right same age healthy chicken from the same flock



Figure 2. Prostration, lying down on the chest and abdomen with the legs open and extended backward – the characteristic posture for SMS



Graph 1. Daily mortality in flock "B"



Graph 2. Daily mortality in flock "A"

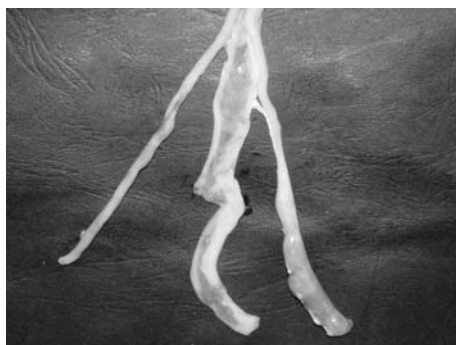

Figure 3. Accumulation of orange-coloured mucoid in hypoglycaemic chickens

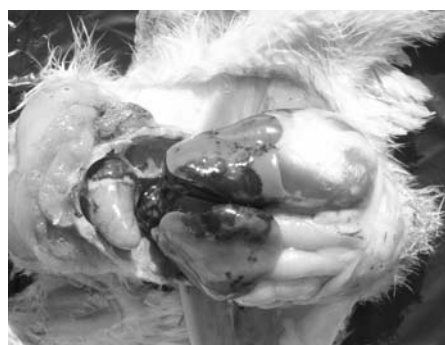

Figure 4. Intensive haemorrhages of liver parenchyma

Plasma blood glucose concentrations in chickens from flock A varied between 3.56 and 10.95 mmol/L, with average value of 6.97 mmol/L. In flock B, the

average blood glucose concentration was 6.31 mmol/L with a range between 3.00 and 10.00 mmol/L. The control samples obtained from healthy chickens, showed mean concentrations of 15.12 and 16.02 mmol/L in flocks A and B, respectively. The plasma of hypoglycaemic chickens was often colourless or pale yellow, compared to the dark yellow colour of unaffected broilers (Fig. 6).

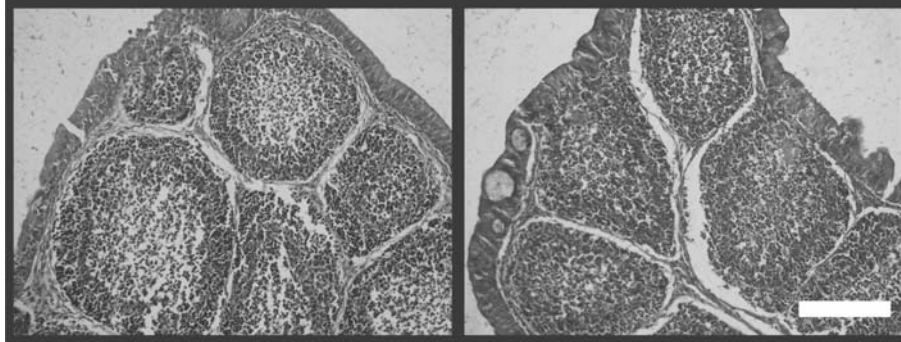


Figure 5. A severe lymphoid deficiency and atrophy of lymphatic follicles in *B. fabricii* (on the left), compared to unaffected *B. fabricii* (on the right), H/E, bar = 50 μ m




Figure 6. Plasma of hypoglycaemic chickens was often colourless or pale yellow (2), compared to the dark yellow colour of unaffected broilers (1)

DISCUSSION

The observed course of SMS in broiler chickens corresponded to reports relative to type A lesions – a more severe course with a short duration, as observed in flock B, and type B lesions – a milder form of a longer duration, as was the case with flock A (Davis, 2003). On the basis of diagnostic investigations on SMS incidence in other farms, we could state that this problem becomes more and more important in pathologies related to poultry production in our country

(unpublished data). We have not observed SMS in broiler parents and stock layers as reported by others (Davis *et al.*, 1995b; Davis, 2003). In studied broiler flocks, our data revealed SMS morbidity and mortality rates (0.5 - 2.00%), similar to those reported in other countries where the problem is common (Davis, 2003). It should be said that the probable cause for the later detection of the syndrome in Bulgaria was its absence during the last 3-4 years. In the beginning of the 2000-ties, there were cases with a similar course to that described in this paper (age of onset, clinical signs, morbidity, mortality), but they were associated with aflatoxin involvement. In fact, the mycotoxicological analysis of feed samples has shown aflatoxin concentrations higher than the maximally allowed ones, but at that time, blood glucose concentrations in affected chickens have not been assayed (unpublished data). This should be considered in the differential diagnosis of SMS, as well as the possible involvement of mycotoxin in the etiology of the syndrome (Hess *et al.*, 1995).

The clinical signs and the gross pathological findings after necropsy are important to make a tentative diagnosis, but the results of blood glucose determination are decisive with regard to SMS confirmation. The average blood glucose levels of 6.97 and 6.31 mmol/L for flocks A and B, respectively were 2-2.5 times lower than the critical values of 15.00 mmol/L (Davis, 2003). The leading macroscopic finding in our studies was intensive parenchymatous haemorrhage in over 60% of chickens from flock B. Comparing the lesion with those already described in the literature, the haemorrhages in our study appeared more severe, but we have not observed necrotic alterations, although they are reported to be rarely seen in recent cases (Davis *et al.*, 1995a; Davis *et al.*, 1995b; Davis *et al.*, 1996; Davis *et al.*, 1997).

We have not carried out any investigation on the etiology of the problem and therefore are not able to discuss it. In general, we accept the common view about an unknown etiology, despite an infectious etiology is suspected (Davis, 2003).

The observed blindness in surviving chickens was probably the cause for their retarded growth.

Address for correspondence:
Dian T. Kanakov MD
Trakia University, Faculty of Veterinary Medicine
Department of Internal Non-infection Diseases
6000 Stara Zagora, Bulgaria
E-mail: dian@gbg.bg

REFERENCES

1. Brown T, Brunet P, Odor E, Murphy D, Mallinson E, 1991, Microscopic lesions of naturally occurring and experimental "spiking mortality" in young broiler chickens, *Avian Dis*, 35, 481-6.
2. Craig F, 1991, Delmarva mortality task force summary. Proc 26th Natl Meet Poult Health Condemn, Ocean city, MD, 12-28.
3. Davis J, De La Torre C, Teng M, Castro A, Doman J, Noble T *et al.*, 1995a, Spiking mortality syndrome in chickens, *Vet Rec*, 136, 204.

4. Davis J, Castro A, De La Torre C, Scanes G, Vasilatos-Younken R, Doman J et al., 1995b, Hypoglycemia and spiking mortality in Georgia chickens: experimental reproduction in broiler breeder chicks, *Avian Dis*, 39, 162-74.
5. Davis J, Castro A, De La Torre C, 1995c, Experimental reproduction of hypoglycemia and spiking mortality in broiler breeder chicks, *Vet Rec*, 136, 107-8.
6. Davis J, Castro A, De La Torre C, Barnes H, Doman J, Metz M et al. 1996, Experimental reproduction of severe hypoglycemia and spiking mortality syndrome using embryo-passaged end field-derived preparations, *Avian Dis*, 40, 158-72.
7. Davis J, De La Torre C, Castro A, Connolly B, Doman J, Dun P, 1997, Experimental reproduction of hypoglycemia-spiking mortality syndrome in broiler chickens with the use of homogenized brains containing arenaviruslike particles, *Avian Dis*, 41, 442-6.
8. Davis J, 2003, Hypoglycemia-spiking mortality syndrome of broiler chickens. in: Diseases of poultry, 11th ed., edited by Saif Y.M., A Blackwell Publishing Company, Iowa State University Press, 1181-3.
9. Goodwin M, Hill D, Dekish M, Putnam M, 1993, Multisystemic adenovirus infection in broiler chicks with hypoglycemia and spiking mortality, *Avian Dis*, 37, 625-7.
10. Hess J, Bilgili S, Kelli T, Shelby R, Casper H, 1995, Mold and mycotoxin levels in feeds from farms experiencing spiking mortality, *J Appl Poultry Res*, 4, 211-4.
11. Mendelson C, Nothelpher H, Monreal G, 1995, Identification and characterization of an avian adenovirus isolated from a "spiking mortality syndrome" field outbreak in broilers on the Delmarva Peninsula, USA, *Avian Pathol*, 24, 693-706.

SINDROM NAGLOG UGINUĆA BROJLERA – KLINIČKA I PATOMORFOLOŠKA ISPITIVANJA SLUČAJEVA U BUGARSKOJ

DINEV I i KANAKOV D

SADRŽAJ

Izvršena su klinička i patomorfološka ispitivanja na dva jata brojlera sa po 20.000 pilića posle pojave nervnih simptoma i iznenadnog povećanja broja uginuća. Morbiditet i mortalitet su praćeni na osnovu kliničkih znakova i rezultata obukcije. Od bolesnih pilića je uzorkovana krv radi utvrđivanja glikemije. Naši rezultati ukazuju na nizak morbiditet, visok mortalitet i izrazito slabiji rast.

