

**PATHOLOGICAL, CLINICAL AND BIOCHEMICAL INVESTIGATION OF NATURALLY OCCURRING PREGNANCY TOXEMIA OF SHEEP**

KABAKCI N, YARIM G, YARIM M, DURU Ö, YAGCI BB and KISA Ü

*\*University of Kirikkale, Faculty of Veterinary Medicine, Department of Pathology*

*\*\*University of Kirikkale, Faculty of Veterinary Medicine, Department of Biochemistry*

*\*\*\*University of Kirikkale, Faculty of Veterinary Medicine, Department of Internal Medicine*

*\*\*\*\*University of Kirikkale, Faculty of Medicine, Department of Biochemistry*

(Received 21. October, 2002)

*A sick ewe in late pregnancy presented with clinical incoordination, lipping, amaurosis, head tilt gait and nervous symptoms such as circling movements. A smell of ketones on the breath was detected. The sick animal died during clinical examination and, together with three more dead animals belonging to the same flock, was submitted to the laboratory for necropsy. The uteri of all pregnant animals contained late-term twin fetuses. The most prominent lesion was extensive fatty infiltration of the liver. Massive lipidoses and lipid vacuoles were seen in sections of the livers. In three brains, there was prominent vacuolation in the white matter. Urine analysis revealed ketonuria in most of the suspected sheep from the same flock. Serum glucose, cholesterol, high density lipoprotein cholesterol, and blood urea nitrogen concentrations were lower ( $p \leq 0.05$ ) and serum triglycerides, aspartate aminotransferase and alanine aminotransferase activities were higher ( $p \leq 0.05$ ) in these sheep than in the controls.*

*After a change of diet and treatment, with glucose and dexamethasone serum glucose levels significantly increased ( $p \leq 0.001$ ) and urine ketone bodies decreased but the other biochemical differences remained.*

*Key words: Biochemistry, pathology, pregnancy toxemia, sheep*

**INTRODUCTION**

Pregnancy toxemia is a metabolic disease that commonly affects pregnant ewes and does during late gestation. Affected animals are generally pregnant with multiple fetuses and in their last month of gestation (Rook, 2000; Van Saun, 2000). It is characterised by hypoglycaemia, low concentrations of hepatic glycogen, increased concentrations of ketone bodies in the blood (hyperketonaemia) and elevated plasma concentrations of free fatty acids (Lindsay and Pethick, 1983; Wastney *et al.*, 1983; Van Saun, 2000). The clinical signs associated with pregnancy toxemia can occur in pregnant individuals with normal body condition, in preg-

nant animals that appear overconditioned, or in thin pregnant animals (Rook, 2000).

Overconditioned individuals typically exhibit severe fatty degeneration of the liver. The gross appearance of the fatty liver is highly characteristic (Rook, 2000; Van Saun, 2000).

The aim of this study was to compare blood and urine biochemical findings of affected, treated and control animals.

## MATERIALS AND METHODS

### *Animals and samples*

Pregnant sheep and all those suspected to have toxemia were individually examined and respiratory rate, rectal temperature, and heart rate were recorded. Urine analysis including leukocyte counts, nitrate, urobilinogen, protein, pH, erythrocyte, specific gravity, ketone, glucose was performed with Bayer Multistix 10 SG®.

Twenty days after the initial therapy, physical examination and urine analysis of the animals were repeated.

A sick three and a half-year old Akkaraman spp. ewe died during clinical examination. This sick animal and three other dead sheep belonging to the same flock were directly submitted to our laboratory for necropsy. The tissues were immediately fixed in Bouin's fixative overnight at 4°C. Subsequently, tissues were dehydrated in ethanol and xylene and embedded in paraffin wax. Serial sections of each tissue were cut on a microtome at 5 µm thickness. The first sections of the tissues were stained with haematoxylin and eosin. Frozen sections of the livers were stained by the Oil red O method.

### *Biochemical methods*

Blood samples were collected by jugular venepuncture. The levels of glucose, triglyceride, cholesterol, high density lipoprotein cholesterol (HDL-C), low density lipoprotein cholesterol (LDL-C) and blood urea nitrogen (BUN), as well as aspartate aminotransferase (AST-EC 2.6.1.1) and alanine aminotransferase (ALT-EC 2.6.1.2) activities were determined in serum samples on a Beckman CX-7 autoanalyser using commercial kits (Sigma Chemical Co. Ltd., Poole, Dorset, UK).

### *Statistical evaluation*

The significance of differences between the controls and affected groups was determined using the Wilcoxon test, and significant differences between before treatment and after treatment times were identified by the t-test (Wayne, 1991).

## RESULTS

### *Clinical Findings*

A three and a half-year old Akkaraman spp. ewe arrived at the University of Kirikkale, Faculty of Veterinary Medicine with a history of incoordination, lipping, reluctance to walk, teeth gnashing, amaurosis, head tilt gait and nervous symptoms such as circling movements, wandering, chewing movements with salivation. According to the owner this was a problem in the flock on his farm and also for other flocks in that area.

On referral to the Faculty of Veterinary Medicine, Department of Internal Medicine, the sheep was hypothermic ( $T=36^{\circ}\text{C}$ ; reference range= $38-39.5^{\circ}\text{C}$ ), depressed and approximately 8 per cent dehydrated. It was in late pregnancy. At physical examination, the heart rate was 120 beats/min (reference range= $70-90$  beats/min) and tachycardia was evident. The respiratory rate was decreased and superficial (8 breaths/min; reference rate =  $10-20$  br./min). The type of respiration was abdominal. A smell of ketones was detected on the breath which strongly suggested pregnancy toxemia.

Urine analysis was unremarkable, except for ketonuria (urine ketone bodies = +++ with Bayer Multistix 10 SG®). An investigation and examination of the flock was made at this farm. According to the farmer, the disease was frequently seen, especially in twin pregnancies, although abortions did not occur. Spontaneous recovery was observed in some of the sick sheep after lambing. The sheep were kept inside sheep barns all the season due to the bad weather conditions and their activities were restricted.

All suspected and especially pregnant sheep were individually examined and respiratory rates, rectal temperatures and heart rates were recorded. No abnormalities were detected. At physical examination apathy, anorexia, weight lost, lethargy and rapid incapacitation were detected. In some of the lambs, pica and insufficient growth was observed.

Ketonuria and urine pH level less than or equal to  $\text{pH}= 6$  were detected in most of the suspected sheep.

We recommended the farmer to change the ration of the animals completely, to give them high quality roughage and the concentrated feed divided in to three equal portions each day. Supportive therapy consisting of 10 per cent glucose solution i.v. was administered to all animals showing clinical signs in order to raise the blood glucose levels. Dexamethasone DEVAN® (2-3 mg/50 kg i.m.) was given in order to stimulate gluconeogenesis.

Twenty days after the initial therapy, physical examination and urine analysis of the animals were repeated. The amount of urine ketone bodies was decreased to trace levels. Clinical symptoms were not observed.

### *Biochemical findings:*

The concentrations of glucose, triglyceride, cholesterol, HDL-C, LDL-C and BUN and activities of AST and ALT in the affected animals, treated animals and controls are presented in Table 1.

Table 1. Biochemical findings in control, toxemic and treated animals (mean  $\pm$  SE).

	Glucose (mg/dl)	Triglyceride (mg/dl)	Cholesterol (mg/dl)	HDL-C (mg/dl)	LDL-C (mg/dl)	BUN (mg/dl)	AST (IU/L)	ALT (IU/L)
Controls n=8	61.5 $\pm$ 3.4	56.8 $\pm$ 1.6	75.8 $\pm$ 5.2	49.0 $\pm$ 3.3	26.1 $\pm$ 3.6	25.8 $\pm$ 1.9	44.1 $\pm$ 5.4	16.4 $\pm$ 1.1
Toxemic animals n=20	31.8 $\pm$ 2.4	100.4 $\pm$ 3.8	43.2 $\pm$ 1.3	11.5 $\pm$ 0.7	29.9 $\pm$ 1.5	9.2 $\pm$ 1.0	192.5 $\pm$ 17.1	54.3 $\pm$ 2.6
Treated animals n=20	51.5 $\pm$ 2.1	99.2 $\pm$ 3.6	43.1 $\pm$ 1.3	12.8 $\pm$ 0.9	28.5 $\pm$ 1.3	9.3 $\pm$ 1.0	190.0 $\pm$ 15.6	54.2 $\pm$ 2.6

Ewes with clinical signs of pregnancy toxemia had serum glucose, cholesterol, HDL-C, LDL-C and BUN concentrations lower than those in the control group ( $p \leq 0.05$ ).

Serum triglyceride concentrations and AST and ALT activities were found to be higher ( $p \leq 0.05$ ) in the sheep with pregnancy toxemia than in healthy sheep. There was a difference between the serum LDL-C concentrations in controls or in affected animals ( $p \leq 0.05$ ).

After treatment, serum glucose levels in the diseased animals were significantly increased ( $p \leq 0.001$ ). Triglyceride, cholesterol, HDL-C and BUN contents and AST and ALT activities were not significantly changed after treatment of affected animals when compared with values before treatment ( $p \geq 0.05$ ). After treatment, serum LDL-C concentrations in the diseased animals were not significantly decreased ( $p > 0.05$ ).

#### *Macroscopic findings:*

All affected animals were in good condition at necropsy and their pregnancies were prominent. The uteri of all pregnant animals contained late-term twin fetuses. In one of them, both fetuses were icteric, but the other fetuses did not show any pathological lesion. The most prominent lesion of the sheep at necropsy was extensive fatty infiltration of the liver. The affected liver was pale yellow in colour, enlarged and easily friable. There was no gross lesion in the other organs on macroscopic examination.

#### *Microscopic findings:*

In all affected animals, massive lipidosis was seen in hepatocytes of the liver (figure-1). The lipidosis was confirmed by Oil red O stain which coloured the lipid vacuoles red.

In three brains, there was prominent vacuolation in the cerebral and cerebellar white matter (figure-2). Astrocytosis and astrogliosis were seen especially around the vacuolation areas. Also perivascular mononuclear cell infiltration in to

both parenchyma and meninges as well as neuronal cell necrosis was seen in the cerebrum and cerebellum.

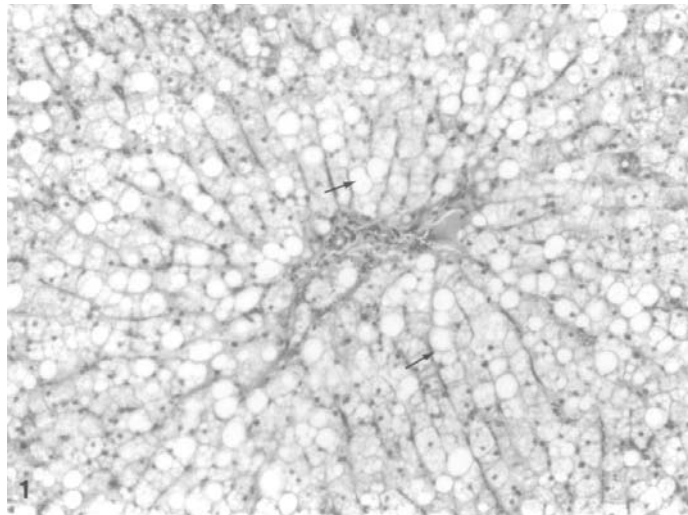


Figure 1. Massive lipidosis in hepatocytes (arrows), Haematoxylin and Eosin. x20

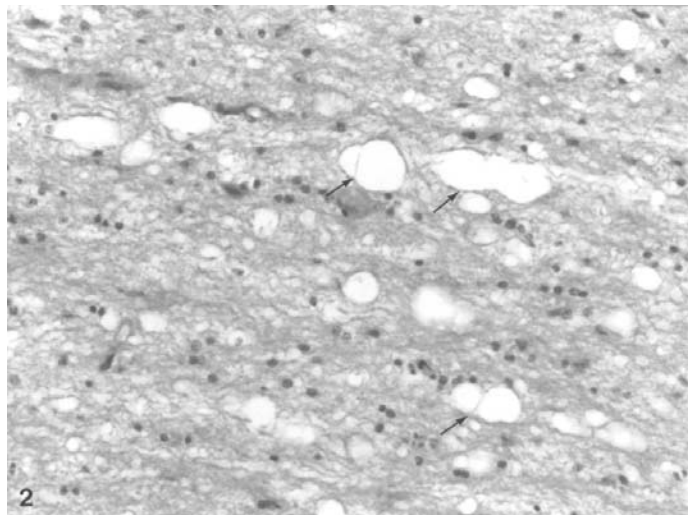


Figure 2. Prominent vacuolation in white matter of the brain (arrows), Haematoxylin and Eosin. x20

## DISCUSSION

Obese pregnant goats are more at risk for developing lactational ketosis once kidding occurs. When flock or herd outbreaks occur, morbidity is often high, approaching 5 % to 20 % of the ewes or does on the farm. Mortality rates of untreated individuals often exceed 80 % and economic losses can be substantial (Rook, 2000). A smell of ketones detected on the breath is strongly suggestive of pregnancy toxemia.

Fatty liver was the most prominent necropsy finding in the present study. Fatty liver is especially common in ruminants with high energy demands, such as those in peak lactation or late gestation. As a result of increased mobilisation of lipids from adipose tissue there is increased entry of lipids into the liver. In pregnant and lactating animals there is an increased demand for glucose and amino acids, and ketosis results when fat metabolism becomes excessive, in response to the increased energy demands. Overconditioned individuals typically exhibit severe fatty degeneration of the liver. Regardless of the cause, the gross appearance of the fatty liver is highly characteristic. With progressive accumulation of lipid, the liver enlarges and becomes yellow. However, practitioners should use caution when interpreting hepatic fat levels. Elevated hepatic fat levels (normal 3 % fat, elevated up to 30 % fat) are a normal occurrence during late pregnancy in the ewe (Rook, 2000; Van Saun, 2000).

Histopathologic investigation of the brain is rarely performed although, cerebrocortical neuronal necrosis along with astrocytic nuclear swelling, hypertrophy, and proliferation have been reported. In the present study, vacuolation of cerebral and cerebellar subcortical white matter and purkinje cell necrosis were seen (Jeffrey and Higgins, 1992). These findings support the theory that clinical signs of pregnancy toxemia result from hypoglycemic encephalopathy (Rook, 2000).

Pregnancy toxemia of ewes and does appears to occur when the animal cannot meet the glucose demands of the fetal-placental unit and hypoglycemia develops. There is individual variation in susceptibility, and there may be basic differences in glucose metabolism between susceptible animals and nonsusceptible animals (Marteniuk and Herdt, 1988).

The relationship between the severity of neurological symptoms and depth of hypoglycemia (McClymont and Setchell, 1955 and 1956) provides additional clinical evidence of hypoglycemic encephalopathy. In later stages of the disease they may enter renal failure and have an altered acidbase status.

Ewes with clinical signs of pregnancy toxemia have serum ketone body (acetoacetate plus beta-hydroxybutyrate) concentrations in excess of 3.0 mM. Our biochemical data were therefore typical of pregnancy toxemia and by extrapolation the ewes probably experienced periods of hypoglycemia. Blood glucose concentrations between 20 and 40 mg/dl (1.2 and 2.2 mM) are common in pregnancy toxemia, although comatose animals may show terminal hyperglycemia, especially associated with fetal death (Marteniuk and Herdt, 1988).

Ischemia, hypoglycemia and epilepsy affects energy metabolism by arresting or impeding cellular energy production or pathologically enhancing energy

consumption (Auer and Siesjo, 1988). There are differences in neuronal revival times, lesion topography and the time course of neuronal death in both natural and experimental models of these disorders (Agard *et al.* 1980; Auer and Siesjo, 1988). Hypoglycemic encephalopathy may become irreversible in the later stages of pregnancy toxemia (Burswell *et al.*, 1986).

Plasma glucose concentrations of spontaneous ovine pregnancy toxemia cases were significantly lower compared to inappetant ewes and healthy ewes at a similar stage of gestation (Henze *et al.*, 1994; Scott *et al.*, 1995). In our study, serum glucose contents of ewes with pregnancy toxemia were also found to be lower ( $p \leq 0.05$ ) than in healthy ewes.

It has been reported that serum total lipid concentrations increase in ketosis (Marteniuk, 1988; Kaneko *et al.*, 1997) which is confirmed in this study.

Serum cholesterol levels significantly decrease in hepatic insufficiency (Kaneko *et al.*, 1997). In the present study, serum concentrations of cholesterol in the affected ewes were lower than in healthy ewes ( $p \leq 0.05$ ). It was found that the blood levels of HDL-C in the diseased ewes were also lower ( $p \leq 0.05$ ), while LDL-C was slightly increased as compared to the controls. BUN levels of toxemic animals were significantly lower ( $p \leq 0.05$ ), which may have been due to liver damage.

Serum AST and ALT activities were higher and correlated positively with the rise of ketonemia and ketonuria in cows with subclinical ketosis (Peneva and Goranov, 1984). AST and ALT activities increase in mononucleosis, liver damage and kidney infection (Kaneko *et al.*, 1997). In our study, AST and ALT activities differed significantly ( $p \leq 0.05$ ) between affected and healthy ewes. Higher activities of AST and ALT in toxemic animals is associated with liver dysfunction.

After treatment, only serum glucose concentrations increased ( $p \leq 0.001$ ). No other changes in serum biochemical parameters were detected.

Further evidence of pathological findings that are secondary to impaired liver function and that lead to increased circulating toxic metabolites is suggested by subcortical white matter vacuolation. These vacuoles are morphologically consistent with a diagnosis of myelin splitting and intramyelinic edema (Cho and Leibold, 1977), such as is commonly found in hepatic encephalopathy (Hooper, 1975).

Ewes with pregnancy toxemia rarely respond, however, to the administration of glucose, perhaps because in the later stages of disease they may enter renal failure, become dehydrated, and have an altered acid base status (Jeffrey and Higgins, 1992).

Therapy is frequently unsuccessful, but frequent administration of small doses of glucose appears to be beneficial, if the other abnormalities, such as acidosis and dehydration, are controlled (Marteniuk and Herdt, 1988). We recommended to the farmer to change the ration of the animals completely, to give them high quality roughage and to offer the concentrated feed in three equal portions per day. Glucose levels may be raised by infusing 10 per cent glucose solution and stimulate gluconeogenesis with dexamethasone.

In this study, to the authors' knowledge the precautions and the therapy were successful.

Address for correspondence:  
 Dr Nalan Kabakci  
 Faculty of Veterinary Medicine,  
 University of Kirikkale,  
 71450 Yahsihan, Kirikkale, Turkey

#### REFERENCES

1. Agard CD, Kalima H, Olsson Y, Siesjo BK, 1980, Hypoglycemic brain injury. I. Metabolic and light microscopic findings in rat cerebral cortex during profound insulin-induced hypoglycemia and in the recovery period following glucose administration, *Acta Neuropathol (Berl)*, 50, 31-41.
2. Auer RN, Siesjo BK, 1988, Biological differences between ischemia, hypoglycemia and epilepsy, *Ann Neurol*, 24, 699-707.
3. Burswell JF, Haddy JP, Bywater RJ, 1986, Treatment of pregnancy toxemia in sheep using a concentrated oral rehydration solution, *Vet Rec*, 118, 208-9.
4. Cho DY, Leipold HW, 1977, Experimental spongy degeneration in calve, *Acta Neuropathol (Berl)*, 39, 115-7.
5. Henze P, Bickhardt K, Fuhrman H, 1994, The contributions of the hormones insulin, cortisol, somatotropin and total estragen to the pathogenesis of sheep ketosis, *Dtsch Tierarztl Wochenschr*, 101: 61-5.
6. Hooper PT, 1975, Spongy degeneration in the central nervous system of domestic animals, Part I: Morphology, *Acta Neuropathol (Berl)*, 31, 325 - 34.
7. Jeffrey M, Higgins RJ, 1992, Brain lesions of naturally occurring pregnancy toxemia of sheep, *Vet Pathol*, 29,301-7.
8. Kaneko JJ, Harvey JW, Bruss ML, 1997, Clinical biochemistry of domestic animals, 5<sup>th</sup> ed., Academic Press, Inc., California, USA.
9. Lindsay DB, Pethick DO, 1983, Dynamic Biochemistry of animal production. Ed. P. M. Biis, Amsterdam, Elsevier, 455.
10. Marteniuk JV, Herdt TH, 1988, Pregnancy toxemia and ketosis of ewes and does, *Vet Clin North Am Food Anim Pract*, 4(2), 307-15.
11. McClymont GL, Setchell BP, 1955, Ovine pregnancy toxemia. II. Experimental therapy with glycerol and glucose, *Aust Vet J*, 31, 170-4.
12. McClymont GL, Setchell BP, 1956, Ovine pregnancy toxemia. IV. Insulin induced hypoglycaemic encephalopathy in the shepp and its implications as regards the pathogenesis of the disease, *Aust Vet J*, 32, 97-109.
13. Peneva I, Goranov KH, 1984, Changes in the serum enzymes and clinical and clinico-biochemical indices of cows with subclinical ketosis, *Vet Med Nauki*, 21, 28-36.
14. Rook JS, 2000, Pregnancy toxemia of ewes, does, and beef cows. *Vet Clin North Am Food Anim Pract*, 16(2), 293-317.
15. Scot, PR, Sargison ND, Penny CD, Pirie RS, Kelly JM, 1995, Cerebrospinal fluid and plasma glucose concentrations of ovine pregnancy toxemia cases, inappetant ewes and normal ewes during late gestation, *Br Vet J*, 151, 39-44.
16. Van Saun R J, 2000, Pregnancy toxemia in a flock of sheep. *J Am Vet Med Assoc*, 217(10), 1536-9.
17. Vasilev B, 1979, Total lipids and cholesterol in the serum of clinically healthy and ketotic cows. *Vet Med Nauki*, 16, 49-54.
18. Wastney ME, Wolff JE, Bickerstaffe R, 1983, Glucose turnover and hepatocyte glucose production of starved and toxaemic pregnant sheep. *Aust J Biol Sci*, 36, 271-84.
19. Wayne WD, 1991, A Foundation for Analysis in the Health Sciences. 5 th Ed., John Wiley& Sons, NewYork.



20. West HJ, 1996, Maternal undernutrition during late pregnancy in sheep, Its relationship to maternal condition, gestation length, hepatic physiology and glucose metabolism, *Br Vet J*, 75, 593-605.

**PATOLOŠKA, KLINIČKA I BIOHEMIJSKA ISPITIVANJA SPONTANO NASTALE  
POROĐAJNE TOKSEMIJE OVACA**

KABAKCI N, YARIM G, YARIM M, DURU Ö, YAGCI BB i KISA Ü

SADRŽAJ

Patološkim i patohistološkim pregeledom četiri ovce koje su uginule pri kraju graviditeta sa blizanačkim trudnoćama utvrđena je masna infiltracija jetre sa lipidozom i masnim vakuolama u hepatocitima. Kod tri jedinke pronađene su i vakuole u beloj moždanoj masi. Pregledom urina jedinki sumnjivih na ovo oboljenje iz istog stada, dokazana je ketonurija a pregledom krvi su utvrđene smanjene koncentracije glukoze, holesterola lipoproteina visoke gustine i uree. Vrednosti serumskih triglicerida D aktivnost jetrinih enzima aspartat aminotransferaze i alanin aminotransferaze su bile povećane. Posle promene hrane i terapije glukozom i deksametazonom povećan je nivo glukoze u krvi i smanjen nivo acetonskih tela u urinu dok su ostali biohemijski parametri bili nepromenjeni.