

Case report

**TRUEPERELLA PYOGENES INDUCED CEREBRAL
ABSCESS IN A WEST HIGHLAND WHITE TERRIER**

USTA Mustafa^{1*}, İLHAN Fatma¹, ÖZEN Hasan¹, İLHAN Ziya²,
KARAMAN Musa¹, KURBAN Muhammed Yusuf³

¹Department of Pathology, Faculty of Veterinary Medicine, Balıkesir University, Balıkesir, Turkey;

²Department of Microbiology, Faculty of Veterinary Medicine, Balıkesir University, Balıkesir, Turkey;

³Institute of Medical Sciences, Balıkesir University, Balıkesir, Turkey

(Received 05 August 2020, Accepted 12 January 2021)

Cerebral abscesses are occasionally seen in animals, however are rare in dogs. Among the pyogenic bacteria causing cerebral abscesses *Trueperella pyogenes* is relatively scarce. In this report, a case of *T. pyogenes* induced cerebral abscess in a West Highland White Terrier was presented with histopathological and bacteriological findings. Two foci of cerebral abscesses located at the level of the thalamus, and the frontal and temporal lobes were described on necropsy. Severe suppurative meningoencephalitis and ventriculitis were noted on microscopic view. *T. pyogenes* was isolated and identified in bacteriological investigation. This report states that *T. pyogenes* can be a causative agent of cerebral abscesses in dogs.

Key words: *Trueperella pyogenes*, cerebral abscess, dog

INTRODUCTION

Trueperella pyogenes, previously named as *Arcanobacterium pyogenes*, *Actinomyces pyogenes*, and *Corynebacterium pyogenes*, is a Gram-positive, pleomorphic, non-spore-forming, non-motile, non-capsulated and facultatively anaerobic rod [1,2]. *T. pyogenes* is a part of normal bacterial flora of the skin, oropharynx, upper respiratory, urogenital, and gastrointestinal tracts of animals. It is an opportunistic pathogen and causes suppurative infection in a variety of organs of domestic, wild, and exotic animals [3]. *T. pyogenes* induced infections are more commonly encountered in cattle and swine [3,4]. However, they are comparably rare in pets animals, and cases of infections characterized by cystitis, wound infection, vaginitis, pneumonia, lung abscess and encephalitis are the reported [2].

In this case presentation gross and microscopic pathological changes related to *T. pyogenes* infection in a dog are described. Since *T. pyogenes* related infections in dogs are rare this case was thought worth of reporting.

*Corresponding author: e-mail: mustafa_usta45@hotmail.com

CASE PRESENTATION

A 6-month-old intact male West Highland White Terrier was presented at a local veterinary clinic in Balıkesir province of Turkey. A history of dullness and lethargy for a period of two days was reported by the owner. Signs of circling, disorientation, head pressing and trismus were also described 12 hours prior to presentation. On clinical examination, the dog was in agony. Physical examination revealed normal body temperature. No blood analysis and radiographic examination were able to be performed since the dog passed away shortly after presentation to the clinic. Hence, the dog was transported for necropsy purposes to the Department of the Pathology, Faculty of Veterinary Medicine, Balıkesir University.

On necropsy, the dog was in normal body condition. There were no signs of head trauma or bites. No signs of inflammation were also noticed in the eyes, ears or mouth. Pathological changes were confined to the brain, and no lesions were seen in any of the other internal organs except the heart. Superficial blood vessels of the cerebral cortex were hyperemic. The right hemisphere was considerably bigger than the left hemisphere due to edema. The right lateral ventricle was significantly dilated. There were two foci of greenish-yellow abscesses, sizing 1.5 cm and 1.8 cm in diameter, located at the level of the thalamus, and the frontal and temporal lobes (Fig. 1). In the epicardium a dark brown degenerated locus sizing 2.5×0.5 cm was located. The lesion was observed to be superficial and not penetrating into the myocardium (Fig. 2). No other lesions were noticed in any of the other examined organs.

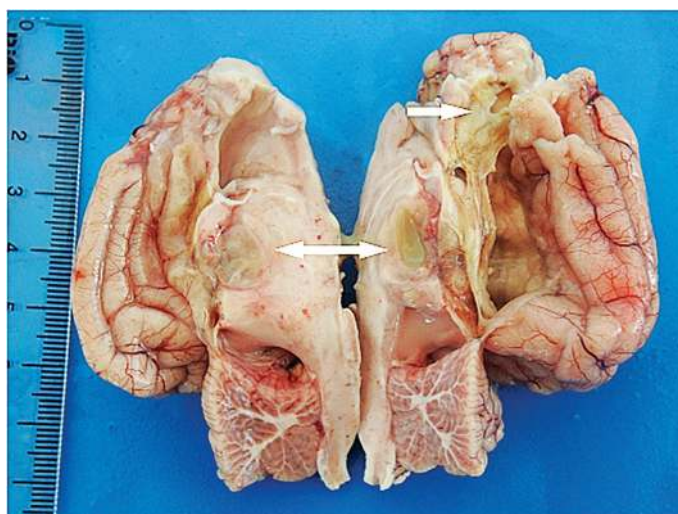


Figure 1. Foci of brain abscesses at the levels of the thalamus (double headed arrow), and the frontal and temporal lobes (arrow).

Tissue samples from the brain and heart were collected and fixed in 10% neutral buffered formalin for routine histopathological examination. The samples were

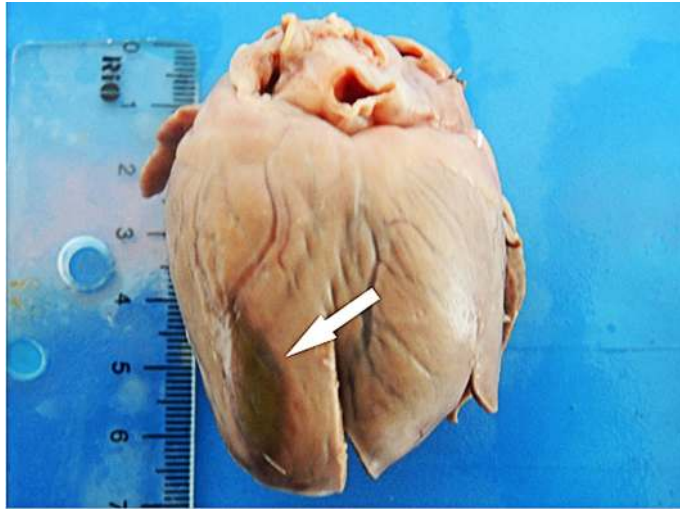


Figure 2. A dark brown degenerate locus in epicardium (arrow).

routinely stained with hematoxylin and eosin (H&E) and the sections were investigated under a light microscope. Histologically, severe suppurative meningoencephalitis and ventriculitis were noteworthy. In microscopic view of the abscess focus located in the thalamic region, classical formation of Splendore-Hoeppli phenomenon, which is a star like eosinophilic-basophilic center surrounded by neutrophils, was seen. No fibrous capsule formation was present (Fig. 3). In the other focus of abscess, neutrophils occupying meninges and the neuropil tissue were observed to be surrounded by a weak formation of the fibrous capsule. Scattered neutrophils and hyperemia were also noted throughout the brain tissue (Fig. 4). No histopathological lesion was noted in the cerebellum. In microscopic view of the heart sample, weak hydropic degeneration was noted in the ectocardium (Fig. 5).

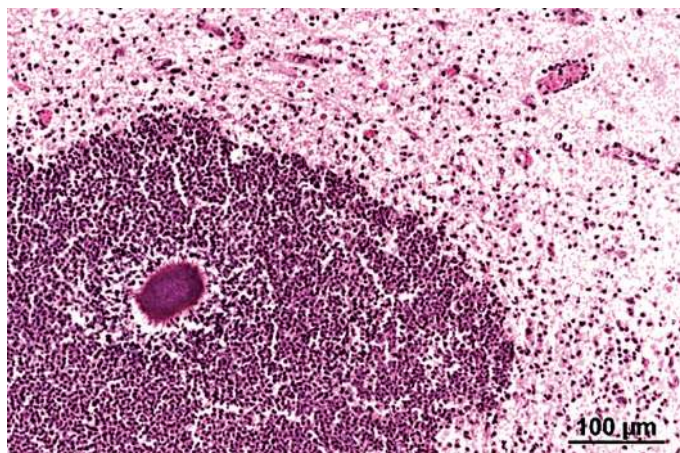


Figure 3. Microscopic view of a brain abscess in thalamic region showing a star like eosinophilic-basophilic center, surrounded by neutrophils. No fibrous capsule formation was noted. H&E.

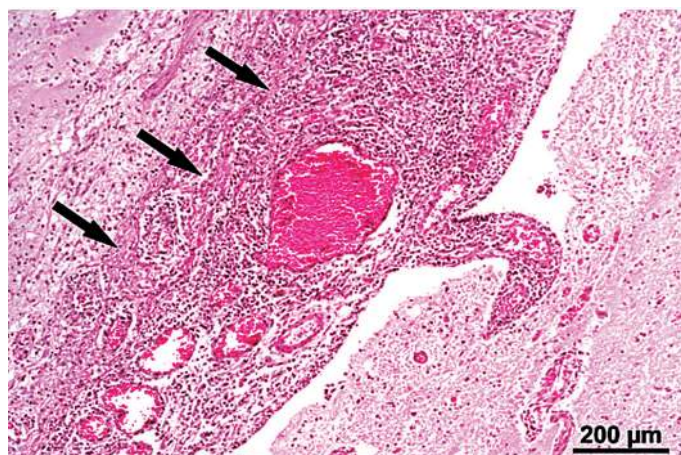


Figure 4. Microscopic view of a brain abscess at the level of frontal and temporal lobes. Note that fibrous capsule formation is in progress (arrows). H&E.

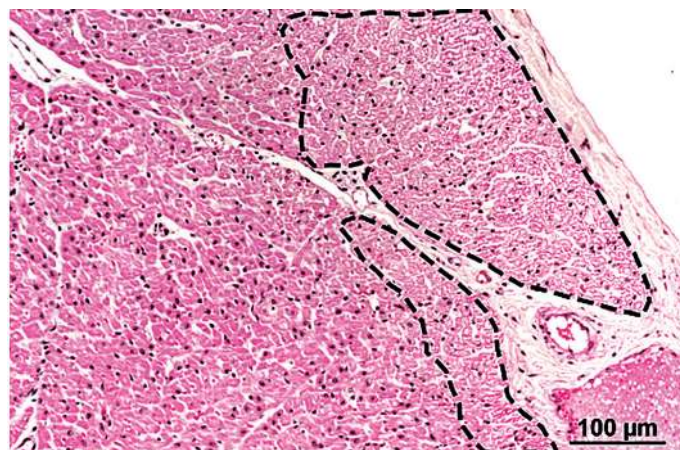


Figure 5. Microscopic view of the epicardium showing weak hydropic degeneration (dotted areas). Note that no inflammatory cells are present. H&E.

For bacteriological analysis, swabs taken from the brain abscesses were immediately inoculated on blood agar base (1.10886.0500, Merck, Darmstadt, Germany), containing 7% defibrinated sheep blood and on MacConkey agar (CM0007, Oxoid, Hampshire, England). The plates were incubated in aerobic and microaerobic conditions (5-10% CO₂) at 37°C for 5-7 days. *T. pyogenes* colonies were visible at 48 hours. Colonies were tiny, pin-pointed, smooth, and surrounded by a narrow zone of hemolysis. *T. pyogenes* was identified based on the macroscopic (colony morphology) and microscopic (Gram stain) morphology, hemolytic activity and conventional biochemical tests. *T. pyogenes* was isolated from the brain abscess as pure culture.

Brain abscess occurs occasionally in domestic and wild animals. In dogs, brain abscesses are comparably less frequent than in other animals. Pyogenic bacteria originating

from a local anatomic location or distant metastatic site might be the cause of these abscesses [5,6]. In this case presentation, *T. pyogenes*-induced brain abscess in a West Highland White Terrier was described pathologically and bacteriologically.

Cerebral abscesses can occur as a result of sinusitis, otitis media, head trauma and neurosurgical manipulation or metastasize from a distant infection such as endocarditis, pulmonary infections, dental infections, and arteriovenous shunts [7]. Immunosuppression was also suggested to be a preliminary factor in the development of a brain abscess in dogs [8]. In some cases of cerebral abscesses, signs of head trauma or a distant infection site can be seen and, hence help to locate the source of the infection [5,9]. However, in the present case, no head lesions or internal organ infections were noted in the dog. Therefore, the source of the infection could not be determined.

Cerebral abscesses can be classified in four stages according to the time: early cerebritis (1-3 days), late cerebritis (4-9 days), early capsule formation (10-13 days), and late capsule formation (after day 14) [7]. However, the time lapse of these stages were described slightly different in some literature [10,11]. Early cerebritis includes neutrophil infiltration, necrosis and edema. Macrophages and lymphocyte accumulation predominate the late cerebritis stage. In the stage of early capsule formation, a well-vascularized thin abscess wall is seen. The last stage of late capsule formation is evident by formation of collagenous and granulation layers. Cases of cerebral abscesses are mostly diagnosed in the last stages of the infection [7]. Similarly, in the present case, a weak formation of the fibrous capsule was observed around one of the foci of abscesses while there was no fibrous capsule formation on the other.

In cerebral abscesses, clinical symptoms of anorexia, lethargy, dullness, seizure, circling, disorientation, head pressing, and trismus are mostly reported [12]. Clinical findings may also vary depending on the location, number and size of the abscesses [13]. Some of these above-mentioned clinical symptoms were also in accordance with the current case. However, clinical examination solely may not be enough in the diagnosis of cerebellar abscess since cerebral tumors, intoxication and systemic infections may cause similar symptoms [14]. Therefore, the definitive diagnosis may require magnetic resonance imaging, computed tomography, blood analyses, and cerebrospinal fluid examination [6,14]. However, in the current case, since the dog passed away shortly after presentation to the clinic, no imaging technique was performed. Hence, final diagnosis was only possible after necropsy, histopathological and bacteriological examinations. Observation of suppurative cerebral lesions and a star like eosinophilic-basophilic center, surrounded by neutrophil leucocytes was the most significant gross and histopathological findings.

Various etiological agents such as *Streptococcus* spp., *Staphylococcus* spp., *Pasteurella* spp., *Fusobacterium* spp. and *Actinomyces* spp. have been described in cerebral abscesses [6,7]. In this case, *T. pyogenes* was isolated and identified from the cerebral lesions. *T. pyogenes* is commonly detected in mastitis, suppurative pneumonia, endometritis,

pyometra, arthritis, and umbilical infection in cattle, sheep and pigs [15]. A case of cerebral abscess in a dog described by Couto et al. stated that the ethological agent was *Actinomyces* spp. [6]. However, the bacterium hasn't been named in species level in cerebral abscesses of dogs previously and this report describes that the cerebral abscess in a dog was induced by *T. pyogenes*.

Little is known about *T. pyogenes* infections. There is no information currently about how this agent disseminates and transmits in the host. There is no sign of evidence that the agent is present in soil and water, however is a part of a common component of the skin and mucous membranes [2]. *T. pyogenes* infections mostly develop as a consequence of mechanical injuries of the skin and mucous membranes [1]. However, no sign of skin or mucous membrane injuries were observed in the present case. Therefore, the source of the infections could not be detected. Only a focus of slight degenerative changes was seen in the epicardium, however this lesion was not correlated with the cerebral abscess.

Authors' contributions

UM performed the necropsy, made histopathological evaluation and writing the manuscript. IF and KM performed the necropsy and contributed to the histopathological evaluation. IZ performed microbiological analysis. OH contributed to the histopathological evaluation and writing. SMY made the first clinical evaluation and necropsy and histopathological investigations.

Declaration of conflicting interests

The author(s) declared no potential conflicts of interest with respect to the research, authorship, and/or publication of this article.

REFERENCES

1. Ribeiro MG, Riseti RM, Bolaños CAD, Caffaro KA, de Moraes ACB, Lara GHB: *Trueperella pyogenes* multispecies infections in domestic animals: a retrospective study of 144 cases (2002 to 2012). Vet Q 2015, 35:82-87.
2. Rzewuska M, Kwiecień E, Chrobak-Chmiel D, Kizerwetter-Świda M, Stefańska I, Gieryńska M: Pathogenicity and virulence of *Trueperella pyogenes*: A review. Int J Mol Sci 2019, 20.
3. Jarosz S, Grański Z, Kalinowski M: *Trueperella pyogenes* infections in swine: Clinical course and pathology. Pol J Vet Sci 2014, 17:395-404.
4. Jaureguiberry M, Madoz LV, Giuliadori MJ, Wagener K, Prunner I, Grunert T: Identification of *Escherichia coli* and *Trueperella pyogenes* isolated from the uterus of dairy cows using routine bacteriological testing and Fourier transform infrared spectroscopy. Acta Vet Scand 2016, 58:1-6.
5. De Castro Cosme J, Da Silva MA, Dos Santos RP, De Andrade PSC, De Carvalho Nunes L: Cerebral abscess in dog - A case report. Rev Bras Med Vet 2015, 37:15-19.

6. Couto SS, Dickinson PJ, Jang S, Munson L: Pyogranulomatous meningoencephalitis due to *Actinomyces* sp. in a dog. *Vet Pathol* 2000, 37:650-652.
7. Erdoğan E, Cansever T: Pyogenic brain abscess. *Neurosurg Focus* 2008, 24.
8. Smith PM, Haughland SP, Jeffery ND: Brain abscess in a dog immunosuppressed using cyclosporin. *Vet J.* 2007, 173:675-678.
9. Wickhorst JP, Hassan AA, Sheet OH, Eisenberg T, Sammra O, Alssahen M: *Trueperella pyogenes* isolated from a brain abscess of an adult roebuck (*Capreolus capreolus*). *Folia Microbiol.* 2018, 63:17-22.
10. Enzmann DR, Britt RR, Obana WG, Stuart J, Murphy-Irwin K: Experimental *Staphylococcus aureus* brain abscess. *Am J Neuroradiol* 1986, 7:395-402.
11. Flaris NA, Hickey WF: Development and characterization of an experimental model of brain abscess in the rat. *Am J Pathol* 1992, 141:1299-1307.
12. Costanzo C, Garosi LS, Glass EN, Rusbridge C, Stalin CE, Volk HA: Brain abscess in seven cats due to a bite wound: MRI findings, surgical management and outcome. *J Feline Med Surg.* 2011, 13:672-680.
13. Muzumdar D, Jhavar S, Goel A: Brain abscess: An overview. *Int J Surg* 2011, 9:136-144.
14. Scahatzberg SJ: Neurologic examination and neuroanatomic diagnosis. In: *Textbook of Veterinary Internal Medicine Expert Consult.* St. Louis, Missouri: Elsevier, Saunders Ltd. 2017, 3290-3308.
15. Quinn PJ, Markey BK, Leonard FC, Hartigan P, Fanning S, Fitzpatrick ES: *Veterinary Microbiology and Microbial Disease.* 2nd ed., West Sussex, UK: John Wiley & Sons. 2011:196-206.

APSCES U MOZGU BELOG WEST HIGHLAND TERIJERA IZAZVAN BAKTERIJOM *TRUEPERELLA PYOGENES*

USTA Mustafa, İLHAN Fatma, ÖZEN Hasan, İLHAN Ziya, KARAMAN Musa,
KURBAN Muhammed Yusuf

Cerebralni apscesi se povremeno nalaze kod životinja, međutim retko se sreću kod pasa. Pored ostalih piogenih bakterija koje izazivaju cerebralne apscese, relativno retko se nalazi *Trueperella pyogenes* vrsta. U radu je prikazan slučaj cerebralnog apscesa kod belog *West Highland* terijera, izazvan sa *Trueperella pyogenes*, zajedno sa histopatološkim i bakteriološkim nalazima. Prilikom obdukcije, opisana su dva fokusa cerebralnih apscesa, locirana na nivou talamusa uz opis frontalnih i temporalnih lobusa. Prilikom mikroskopskog pregleda, uočeni su težak gnojni meningoencefalitis i ventrikulitis. Bakteriološkim pregledom, identifikovan je *Trueperella pyogenes*. Ovaj izveštaj ukazuje da *Trueperella pyogenes* može da bude etiološki faktor cerebralnih apscesa kod pasa.